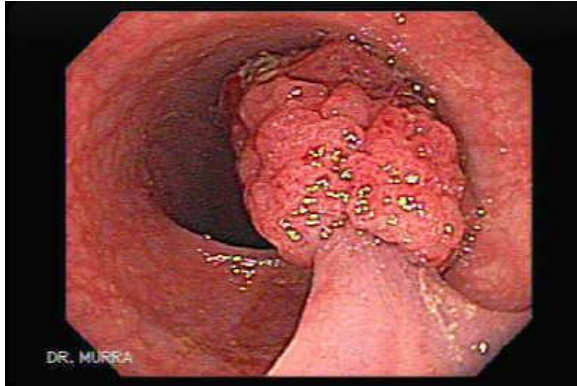


# Colonoscopy OSAT

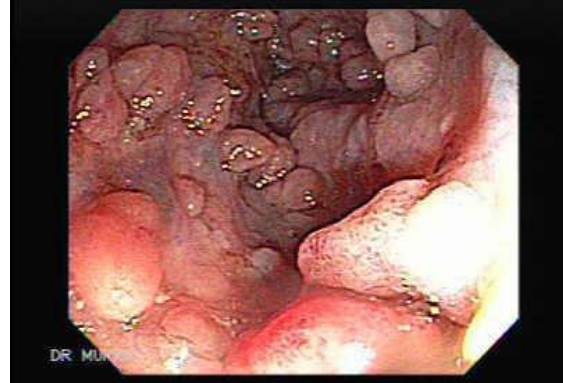
---

1. Please Describe lesion:



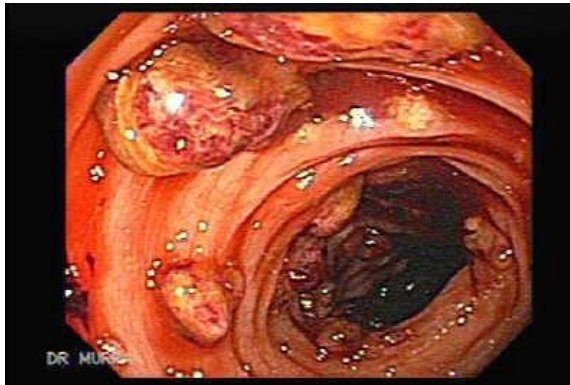
3. Please identify suspected diagnosis

Pt has strong family hx of colon cancer

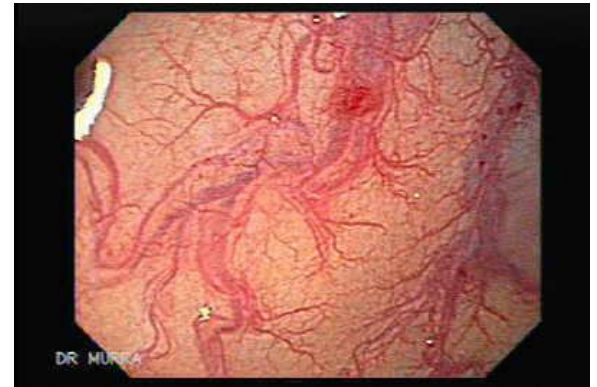

2. Please Describe Finding

Pt hx of refractory C. Difficile Infection  
with grossly distended, acute abd



4. Please describe finding



---

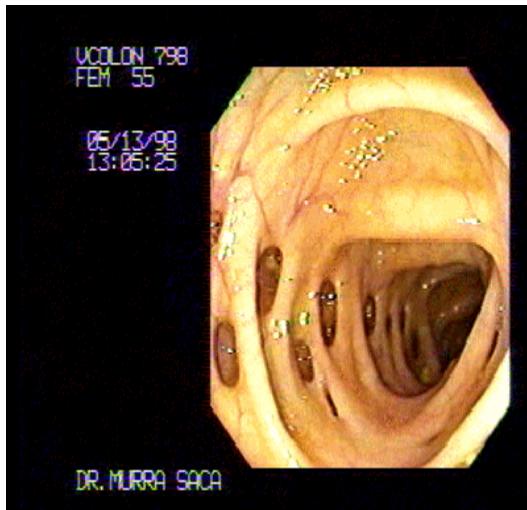
All Images Copyright and Used with Permission of the Author, Julio Murra-Saca, MD. Duplication

and use of images is strictly prohibited.



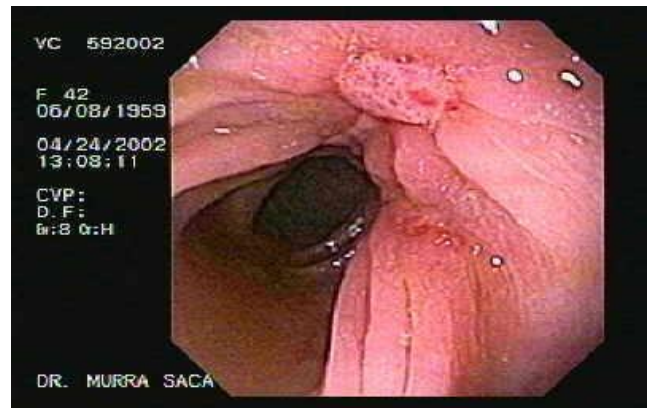
# Colonoscopy OSAT

5. Please describe finding

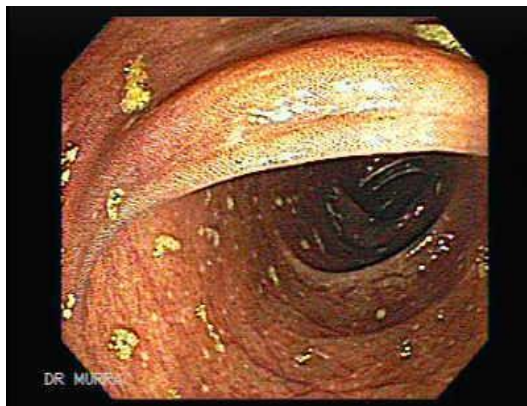

7. Please describe finding and suspected diagnosis

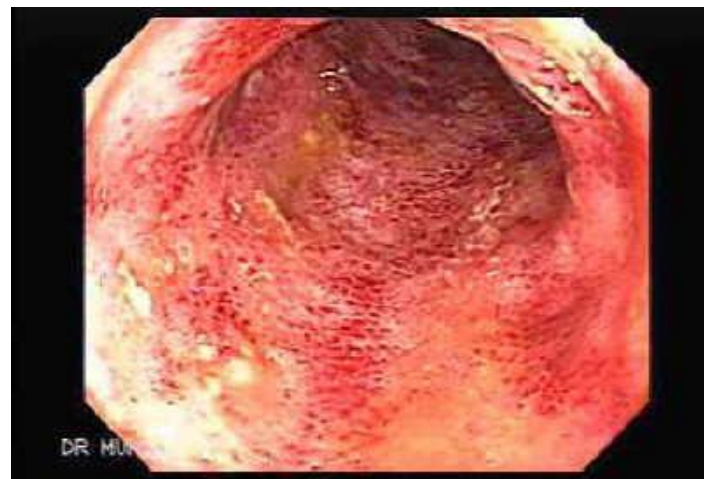Pt has long hx of diarrhea and abd. Pain



6. Please describe finding



8. Please identify suspected diagnosis  
Pt has recent hx of bloody diarrhea and  
Abd pain, finding is consistent thru-out  
colon



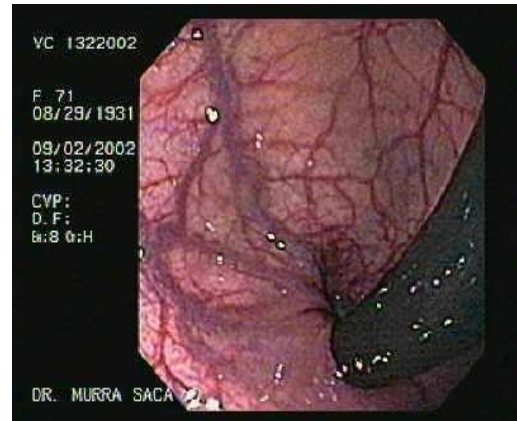
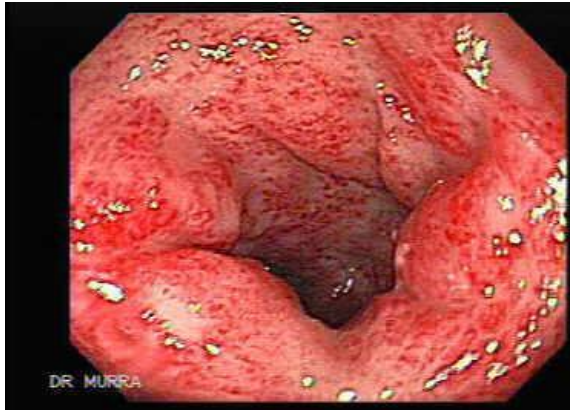All Images Copyright and Used with Permission of the Author, Julio Murra-Saca, MD. Duplication

and use of images is strictly prohibited.

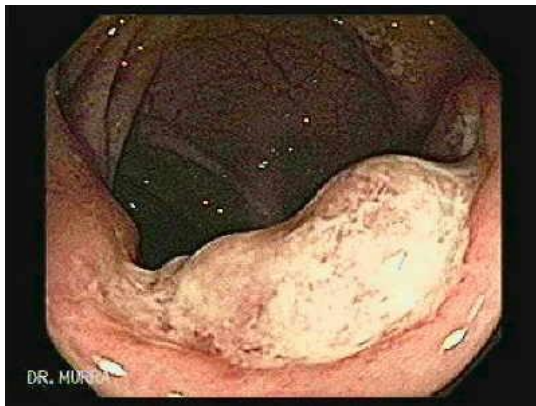

# Colonoscopy OSAT

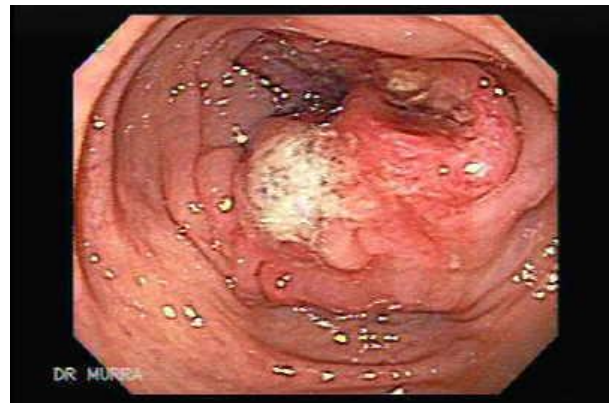
9. Please describe finding  
Pt has hx of rectal cancer s/p  
neoadjuvant therapy



10. Please identify suspected diagnosis  
Pt has hx of cough, fever, abd pain, wt  
loss, HIV + with oropharyngeal  
candidiasis



12. Please describe finding



11. Please describe finding

13. Please identify suspected diagnosis

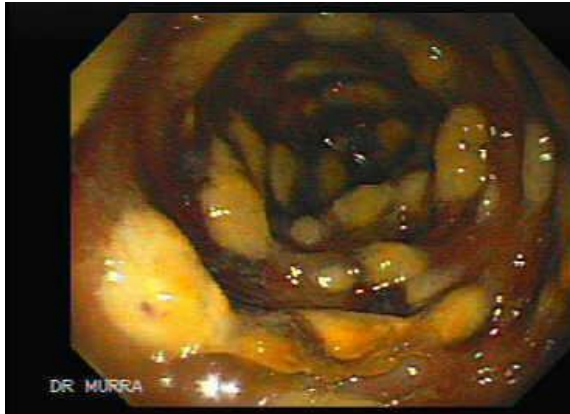All Images Copyright and Used with Permission of the Author, Julio Murra-Saca, MD. Duplication

and use of images is strictly prohibited.

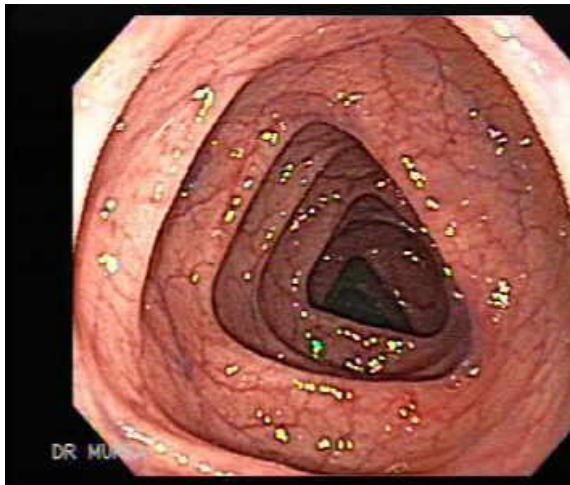


# Colonoscopy OSAT

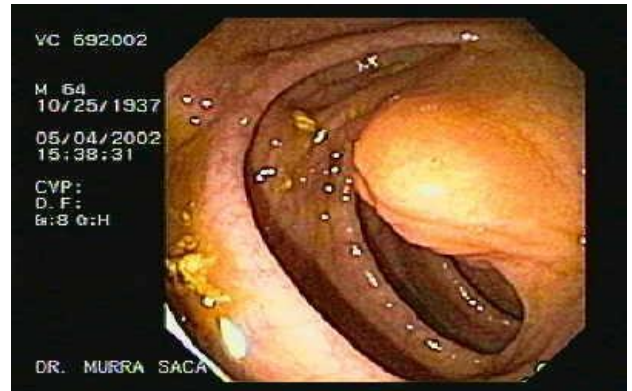
---



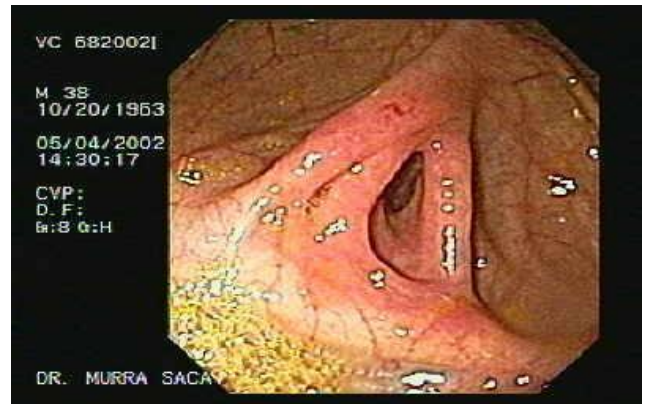
14. Please describe anatomic location of photo



15. Please describe finding



16. Please Describe Finding



17. Please describe finding

---

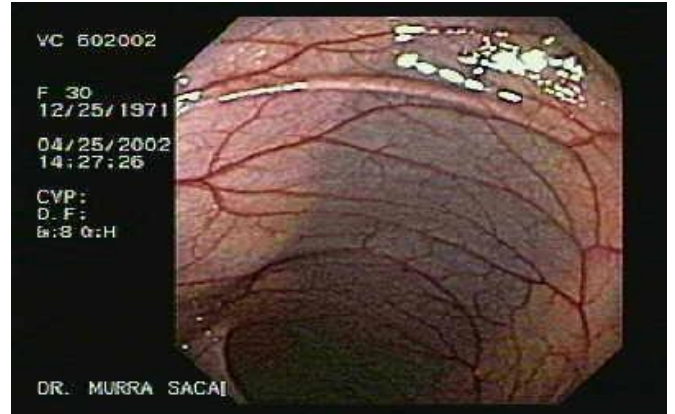
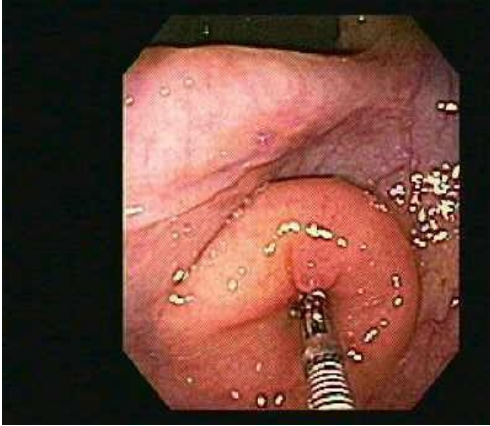
All Images Copyright and Used with Permission of the Author, Julio Murra-Saca, MD. Duplication

and use of images is strictly prohibited.



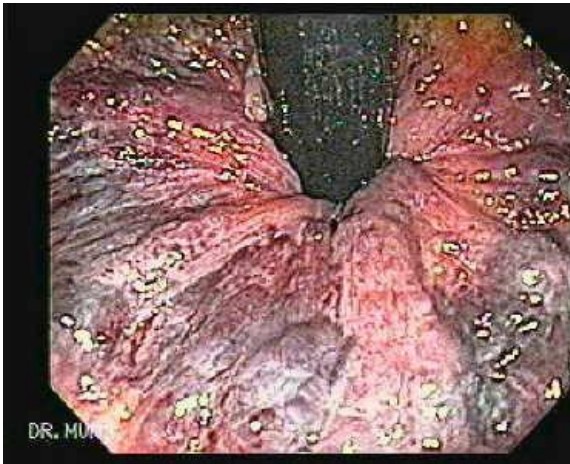
# Colonoscopy OSAT

---



---

18. Please describe finding:



---

19. Please Identify Cause of blue shadow  
seen on Colonoscopy

---

All Images Copyright and Used with Permission of the Author, Julio Murra-Saca, MD. Duplication

and use of images is strictly prohibited.

